

Dr. Smock's Top 25 Serious Medical Consequences Resulting from Strangulation and the Lateral Vascular Neck Restraint

Bill Smock, MD

Police Surgeon, Louisville Metro Police Department

Clinical Professor of Emergency Medicine

University of Louisville School of Medicine

Bill.smock@louisvilleky.gov

502-574-7080

2/19



#1

- Acute Death

- Compression of blood vessels:
jugular veins (2.86 - 4.4 pounds of pressure), carotid artery (11 pounds of pressure) and vertebral arteries (16.5 - 66 pounds of pressure)
- anoxic/hypoxic brain cell death

#2

- Acute Death
 - Compression/occlusion of trachea:
minimum of 34.5 pounds of
pressure on trachea
 - Anoxic/hypoxic brain cell death

#3

- Acute Death
 - Combination of: airway compression, carotid artery occlusion, jugular vein occlusion and suffocation/asphyxia.
 - Anoxic and hypoxic brain cell death from simultaneously compromised airflow and blood flow.

#4

- Delayed Death
 - Anoxic/hypoxic brain cell death
 - Multisystem organ failure
 - Hours to days to months post strangulation/“choke hold”
 - Many victims appeared “normal”

#5

- Acute Thrombotic Stroke
 - Clot develops within the carotid arteries-results in brain cell death
 - Blockage of a single artery kills 32,000 neurons/second, 230 million synapses/second and 218 yards of myelinated fibers/second
 - Present with unilateral weakness

Thrombosed Internal Carotid Artery After the Application of a Carotid Restraint

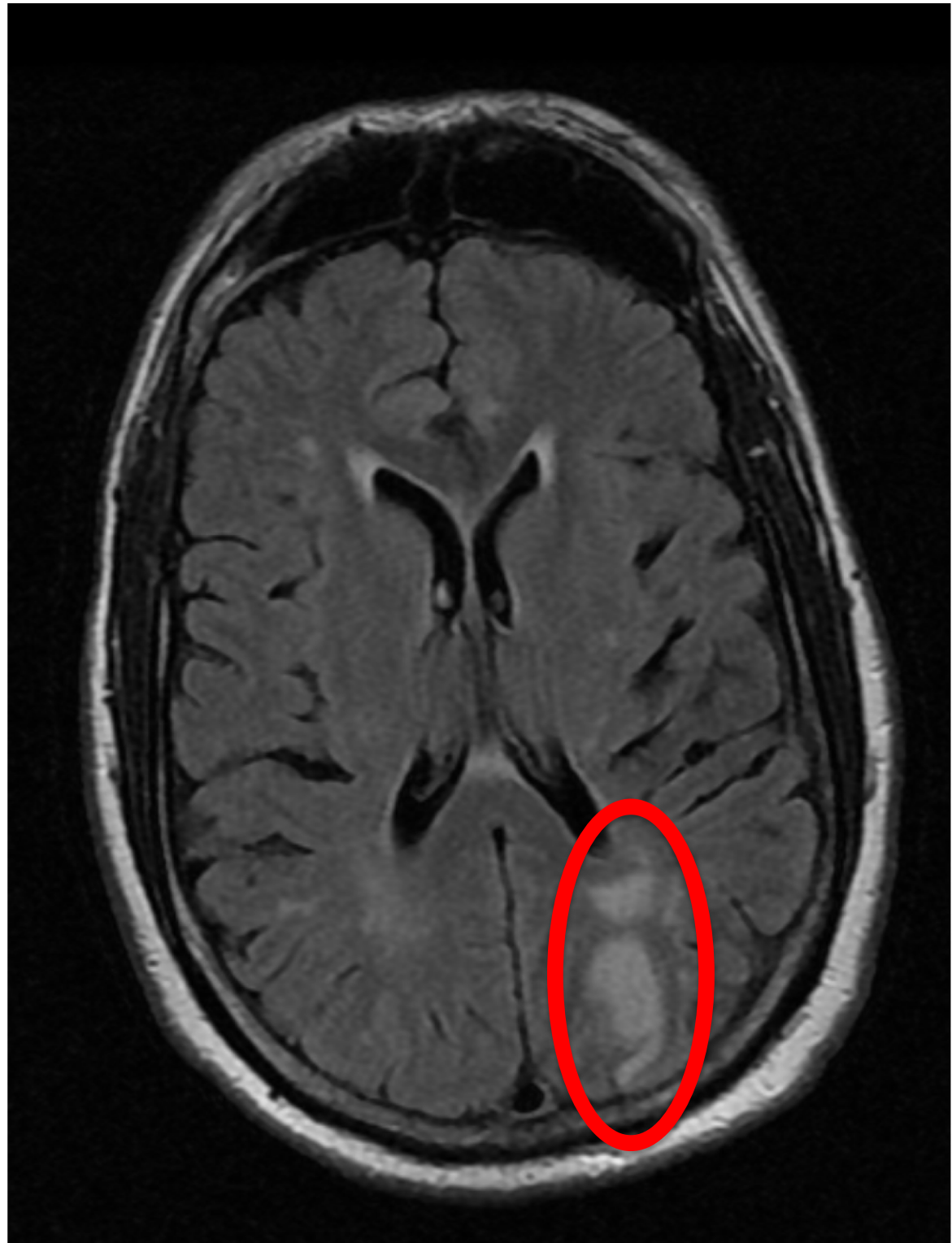


#6

- Acute Embolic Stroke
 - Kentucky police officer developed acute stroke symptoms within 10 minutes after lateral vascular neck restraint training (tapped out while still conscious) when plaque broke off.*
 - Florida Police Academy instructor developed stroke symptoms after lateral vascular neck restraint training

*KY law enforcement officer evaluated by Dr. Bill Smock, 2015

Brain MRI of a Kentucky police officer who developed embolic stroke symptoms 10 minutes after participation in lateral vascular neck restraint training. Plaque in arteries broke off and went to the brain. The MRI demonstrates acute brain infarctions.



#6

- Acute Embolic Strokes
 - Two Fort Wayne, IN Police Officers suffer strokes from LVNR training*.
 - One officer suffered acute right arm paralysis during training
 - One officer suffered a posterior circulation stroke <24 after training

*Fort Wayne PD Officers seen by Dr. Bill Smock, 2019

#7

- Delayed Cryptogenic Strokes
 - Cerebral infarcts from prior anoxic brain damage
 - Occur months to years after the anoxic damage from strangulation or “choke hold”

Strack GB et al, Why Didn't Someone Tell Me? Health Consequences of Strangulation Assaults for Survivors, 2014, Domestic Violence Report;19(6):87-90.

#8

- Acute Anoxic Encephalopathy
 - Brain damage from blockage of blood flow to and from brain
 - Brain damage from decrease oxygen levels in circulating blood
 - “cytotoxic brain edema within seconds to minutes”

M Oechmichen et al “Cerebral Hypoxia and Ischemia: The Forensic Point of View: A Review; J Forensic Science, July 2006, Vol. 51, No. 4:880-887

#8 (Cont.)

- Acute Anoxic Encephalopathy
 - Hippocampus, parieto-occipital-temporal cortex, cerebellar purkinje cells, amygdala, caudate nucleus, lentiform nucleus, thalamic nuclei most sensitive to lack of oxygen
 - Brainstem (medulla-breathing center), hypothalamus and basal forebrain more resistant

#9

- Delayed Anoxic Encephalopathy
 - Brain damage manifests days to weeks after strangulation/choke hold:
 - Blindness
 - Choreoathetosis (movement disorder)
 - Dystonia (movement disorder)
 - Psuedobulbar paralysis
 - Victim appeared “normal”
 - Memory dysfunction

#10

- Cervical Spine Injury
 - Tear of anterior and posterior longitudinal ligaments
 - Spinous process fractures
 - Epidural spinal cord hemorrhage
 - Spinal cord contusion

#10 (cont.)

- Cervical Spine Injury
 - Vertebral body fracture/dislocation (victims were lifted off the ground while in lateral vascular neck restraint)

#11

- Seizures
 - Anoxic convulsions: tonic clonic contraction of muscle groups within 1-3 seconds after loss of consciousness*
 - Abnormal brainwave activity, Delta waves, are seen with the onset of loss of consciousness

*Sauvageau A et al “Agonal Sequences in 14 Filmed Hangings...”,
Am J Forensic Med Pathol; 2011;32: 104-107

#11 (cont.)

- Hypoxic Seizures: “Choking Game”
 - “Sleeper hold”
 - “Cerebral anoxia”
 - “this often results in loss of consciousness and sometimes an hypoxic seizure”*

*Clinical Pediatrics, 49(3)274-279

#12

- Sphincter Incontinence
 - Anoxia of at least 15 seconds resulted in loss of bladder sphincter tone (involuntary urination)
 - Anoxia of at least 30 seconds resulted in loss of rectal sphincter tone (involuntary defecation)

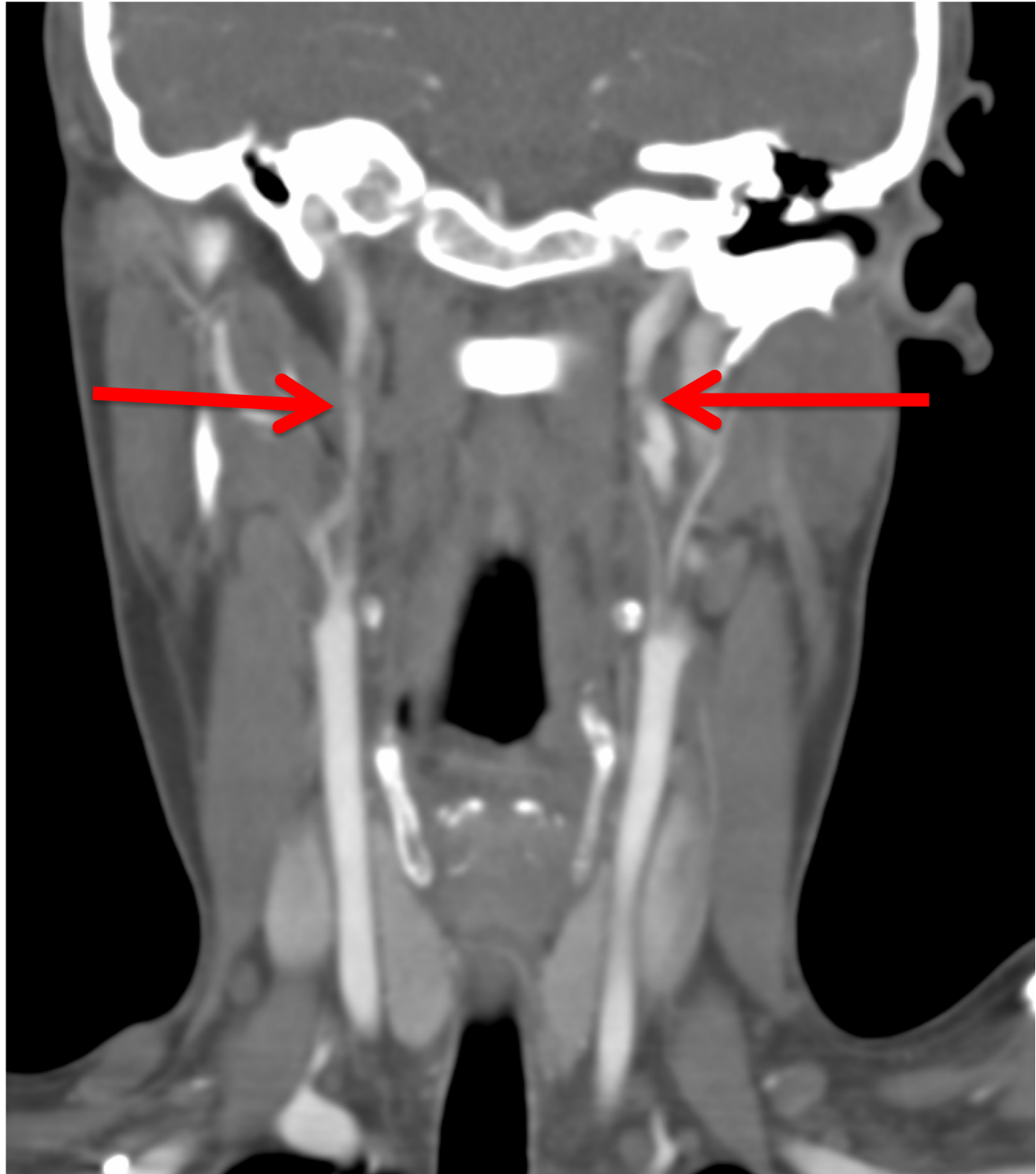
#13

–Carotid Artery Dissection

- Unilateral and bilateral
- Pressure applied to the carotid arteries during strangulation and “choke holds” results in damage (tears) within the vessel
- Death, stroke, long-term therapy

Clarot F et al: Fatal and non-fatal bilateral delayed carotid artery dissection after manual strangulation;Forensic Science International;2005, 149:143-150.

**Bilateral
internal
carotid
artery
dissections
from the
application
of a carotid
restraint.**



#14

- Carotid Artery Hematoma
 - Rupture of the carotid artery permits leakage of blood into the surrounding tissue, creating a hematoma
 - Rupture of the hematoma can cause rapid death, days to weeks after strangulation or “choke hold”

Dayapala A et al: An Uncommon Delayed Sequela After Pressure on the Neck: An autopsy case report, Am J Forensic Med Pathol;2012, 33(1):80-2.

#15

- Jugular Venous Thrombosis
 - Damage to the jugular vein results in the formation of a thrombus (blood clot) within the vessel

#16

- Airway Swelling/Respiratory Failure
 - Pharyngeal, supraglottic, subglottic and laryngeal edema has created life-threatening airway obstruction
 - Respiratory failure secondary to swelling >36 hours post strangulation or application of “choke hold”

Kuriloff DB, Pincus RL:Delayed Airway Obstruction and Neck Abscess Following Manual Strangulation. Ann Otol Rhinol Laryngol. 1989;98:824-7.

#17

- Thyroid Storm
 - Compression of the thyroid gland can cause the release of excess thyroid hormone resulting in thyrotoxicosis
 - Life-threatening symptoms: agitation, hyperthermia, tachycardia, multi-system organ failure

Ramirez J et al, Thyroid Storm Induced by Strangulation, Southern Medical Journal, 2004;97(6);608-610

#18

- Vocal Cord Paralysis (Aphonia)
 - Unilateral or bilateral injury to the recurrent laryngeal nerve from pressure applied during strangulation
 - Aphonia can be temporary or permanent

Peppard SB. Transient vocal paralysis following strangulation injury. Laryngoscope 1982;92:31-33.

#19

- Fracture of the Hyoid Bone
 - Fractures of the hyoid bone occur from the application of pressure to the area above the larynx
 - Hyoid fractures are seen in both surviving and fatal victims of strangulation

Line WS et al: Strangulation: A Full Spectrum of Blunt Neck Trauma; Ann Otol Rhinol Laryngol, 1985, 94:542-46.

#20

- Thyroid Cartilage Fracture
 - Fractures of the thyroid cartilage occur from the application of pressure on the larynx
 - 34.76 pounds of pressure to fracture the thyroid cartilage
 - Life-threatening airway obstruction

Stanley RB, DG Hanson: Manual Strangulation Injuries of the Larynx; Arch Otolaryngol, 1983;109:344-347.

#20

- Fracture of the Cricoid Cartilage
 - Fractures of the cricoid cartilage occur from the application of pressure on the larynx
 - 45.76 pounds of pressure to fracture the cricoid cartilage
 - Life-threatening airway obstruction

Stanley RB, DG Hanson: Manual Strangulation Injuries of the Larynx; Arch Otolaryngol, 1983;109:344-347.

#21

- Dysphagia/Odynophagia
 - Difficulty swallowing, painful swallowing or inability to swallow after strangulation or application of a “choke hold”
 - Causes can include: fractures of: hyoid bone, cricoid or thyroid cartilage, hematoma, soft-tissue swelling

#22

- Hypopharyngeal Rupture
 - Tearing of the structures in the upper airway can result in leakage of air or secretions into the chest cavity
 - Pneumopericardium (air surrounding the heart) has occurred during a strangulation-induced hypopharyngeal rupture*

*Giger R, Pneumopericardium After Manual Strangulation, Am Journal Med, 2004;116,116-118

#23

- Tinnitus (ringing in ears)
 - Aneurysm of carotid artery from a ligature strangulation resulted in nerve injury
 - Symptoms were present for 3 years after the strangulation

YadollahiKhaless G et al, Tinnitus 3 Years After Strangulation, Journal of Nervous and Mental Disease;2015;203(2)154-55.

#24

- Acquired Glottic and Subglottic Stenosis
 - Damage to the larynx and trachea during strangulation can result in the scarring and narrowing of the larynx and trachea

Pookamala S et al, Acquired subglottic stenosis: aetiological profile and treatment Results. Journal of Laryngology and Otology, 2014:128, 641-648

#25

- Post Traumatic Stress Disorder
 - The emotional distress associated with life-threatening events, including strangulation, have long-term psychological consequences

McClane GE, Strack GB, Hawley D. A review of 300 Attempted Strangulation Cases Part II: Clinical Evaluation of the Surviving Victim. J Emerg Med:2001;21(3):311-15.

And

Vella, SA, Cognitions and Behaviors of Strangulation Survivors of Intimate Terrorism, Doctor of Psychology Thesis, California School of Professional Psychology, Alliant International University, 2013.

Additional, beyond the 25 injuries listed, severe and life-threatening injuries are possible from the application of external pressure applied the neck.

Bill Smock, MD
Police Surgeon, Louisville Metro Police Department
Clinical Professor of Emergency Medicine
University of Louisville School of Medicine

Bill.smock@louisvilleky.gov

502-574-7080

12/18